

NIICS Spinal Injuries Evaluation Protocol

GROUP 1 PATIENTS

Defined as trauma victims who fulfil all **4 clinical pre-conditions** below

- 1) Glasgow Coma Scale (GCS) score 15 and appropriate
- 2) Not impaired by intoxicants, alcohol or sedation/opioid analgesics
- 3) No midline spinal tenderness, no deformity or steps and no neurological deficit referable to a spinal injury (eg abnormal tone, power or reflexes)
- 4) No significant distracting injury eg extremity fracture

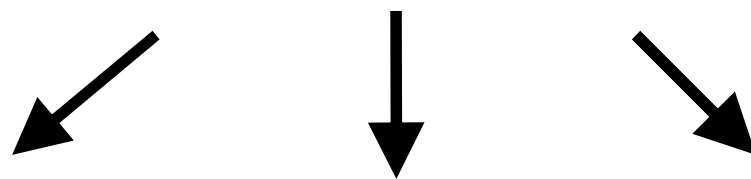
GROUP 2 PATIENTS

Defined as trauma victims who do NOT meet **4 clinical pre-conditions** and are not under care of ICU

GROUP 3 PATIENTS

Defined as trauma victims who do NOT meet **4 clinical pre-conditions** above and are under the care of ICU and/or are intubated eg traumatic brain injury

Trauma victim arrives with full spinal immobilisation applied (cervical collar, sandbags, tape and spinal board). Senior staff assess **4 clinical pre-conditions**



Group 1
Satisfy **all 4 clinical pre-conditions**.
Spine may be regarded as stable and uninjured. Observe during mobilisation*

***Weakness, paraesthesia or pain may indicate a missed injury**

GROUP 2
Do not meet **all 4 clinical pre-conditions** and are not under the care of ICU
Maintain immobilisation as practical and perform

- 1) Lateral, AP and odontoid cervical plain radiographs
- 2) Consider thoracolumbar AP + lateral plain radiographs if appropriate mechanism

Await improved GCS if necessary and apply 4 clinical pre-conditions again. If these satisfied and imaging is normal the spine may be regarded as stable and uninjured. Observe during mobilisation *

GROUP 3
Do not meet **all 4 clinical pre-conditions** and are under the care of ICU or intubated. Perform **entire spinal imaging** before ICU admission ie

- 1) Lateral, AP and odontoid cervical plain radiographs
- 2) Thoracolumbar AP + lateral plain radiographs
- 3) High resolution cervical CT of the craniocervical junction (to C2/C3) and inadequate (eg cervicothoracic junction) or suspicious plain film areas

If **entire spinal imaging** is normal and there are no external signs of spinal injury on clinical examination the spine may be regarded as stable and uninjured. Observe during mobilisation *

Neurological deficit referable to the spine requires urgent consideration of MRI. Management of a detected injury must involve a senior neuro or orthopaedic surgeon.

Explanatory Notes:

This protocol is intended to act as the preliminary screening process and management of spinal injuries amongst trauma victims.

The mechanism of injury may be classified as:

- 1) High energy eg motor vehicle accident or a fall greater than the individual's height.
- 2) Low Energy in association with signs or symptoms of spinal injury eg apparently minor fall or a domestic accident. Up to 15% of spinal injuries may follow such a mechanism.

Immobilisation of “non-cleared” trauma patients

Within this protocol it is anticipated that consultant clinicians will be responsible for declaring the spine stable and “cleared”. Until that point patients must be managed in line with ATLS guidelines:

- 1) In an appropriately fitting *ASPEN* or equivalent semi-rigid collar and use of sand-bags and tape where possible.
- 2) On a firm, flat mattress. The use of spinal boards is under institutional review and ATLS guidelines recommend patients are removed from rigid spinal boards *following the primary survey* (ie within the emergency department).
- 3) All moves or transfers performed as log-rolls with appropriate staff for the patient size.

It is emphasised that the intention of these interventions is to avoid displacing unstable spinal injuries. Amongst agitated, intoxicated or uncooperative patients judgement must be employed as forcible restraint and attempted application of supine immobilisation may promote displacement and active movement of the patient's spine.

Once the spine is “cleared” the patient can be moved cautiously and under supervision. Any subsequent evidence of weakness, spine or neck pain or paraesthesia must be considered as a potential missed injury and be evaluated further, with a low threshold to reinstitute immobilisation

Complications of Immobilisation

Among all patients the restoration of mobility is to be seen as a management priority. Cutaneous ulceration, pneumonia, sepsis and venous thromboembolism are among the more serious complications. The screening of **group 3 patients** is to be completed as rapidly as possible (target to be less than 48 hrs) since the incidence of cutaneous ulceration increases rapidly beyond this time. These can be life-threatening complications, which must be balanced against the very small risks of missing a spinal injury using this protocol.

Plain radiographs

A lateral cervical radiograph, especially in the emergency setting, may miss 15% of cervical injuries and a 3 view cervical series 5-10%: in unconscious patients, plain radiographs **alone** lack sensitivity to clear the cervical spine.

If the middle of C7 cannot be seen on the lateral plain radiograph, under 8% of cases will have the cervicothoracic junction revealed by arm traction: consider using swimmer's or oblique plain film views or CT. **Repeated attempts to obtain further (inadequate) lateral radiographs have risks, waste time and are to be avoided.**

Thoracolumbar spine

Thoracolumbar spinal injury should be strongly suspected if any of the following are present:

- 1) High energy or appropriate impact, unconscious or intoxicated, or distracting injuries
- 2) Spinal tenderness or deformity, or appropriate neurological deficit

Group 3 patients should have routine screening thoracolumbar plain radiographs, and a low threshold should be employed to screen **group 2 patients**. Unlike cervical trauma, isolated ligamentous injury of the thoracolumbar spine is extremely rare and plain radiographs are considered sufficient if technically adequate.

Combined cervical plain radiographs and CT

Among **group 2 or 3 patients** most evidence suggests plain films and directed CT (ie routine craniocervical scanning and further scanning of non-visualised or suspicious plain radiographic areas) performed in a complementary fashion have a high sensitivity for most unstable injuries; missing much less than 1% (including ligamentous injuries).

Due to practical limitations in some hospitals, entire cervical CT may not be offered out of hours. It is anticipated that (when available) entire helical CT will replace directed CT scanning for group 3 patients.

Because of the complications of transferring the critically ill and the implications for subsequent care it is hoped that all but the most unstable patients can have their entire spinal evaluation performed **before** theatre or ICU admission: management of genuinely life threatening injuries must always take precedence over imaging which can be performed at a later date.

MRI and Dynamic Fluoroscopy

Routine use of MRI or dynamic fluoroscopy does not reliably improve performance and is not practical for critically ill trauma victims at present.

Managing Detected Injuries

Once an abnormality is detected on screening, especially following **entire spinal imaging** among group 3 patients, it is essential that this injury and its significance is

assessed by a senior neuro or orthopaedic surgeon; typically in conjunction with a senior radiologist. The determination of stability or otherwise of a detected spinal injury, however apparently trivial, requires specialist advice.

A more complete bibliography and references are available from:

Dr C Morris and Dr G Lavery

Regional Intensive Care Unit

Royal Victoria Hospital

Belfast

e-mail: cmorris@doctors.org.uk